

3rd International Symposium on Clinical and Economic Aspects of Osteoporosis and Osteoarthritis

Barcelona / Spain, November 6-9, 2002

Intra-articular hyaluronic acid in osteoarthritis of the carpometacarpal joint

Dr. med. Martin Talke

Practice for Orthopaedics and Rheumatology, Berlin, Germany

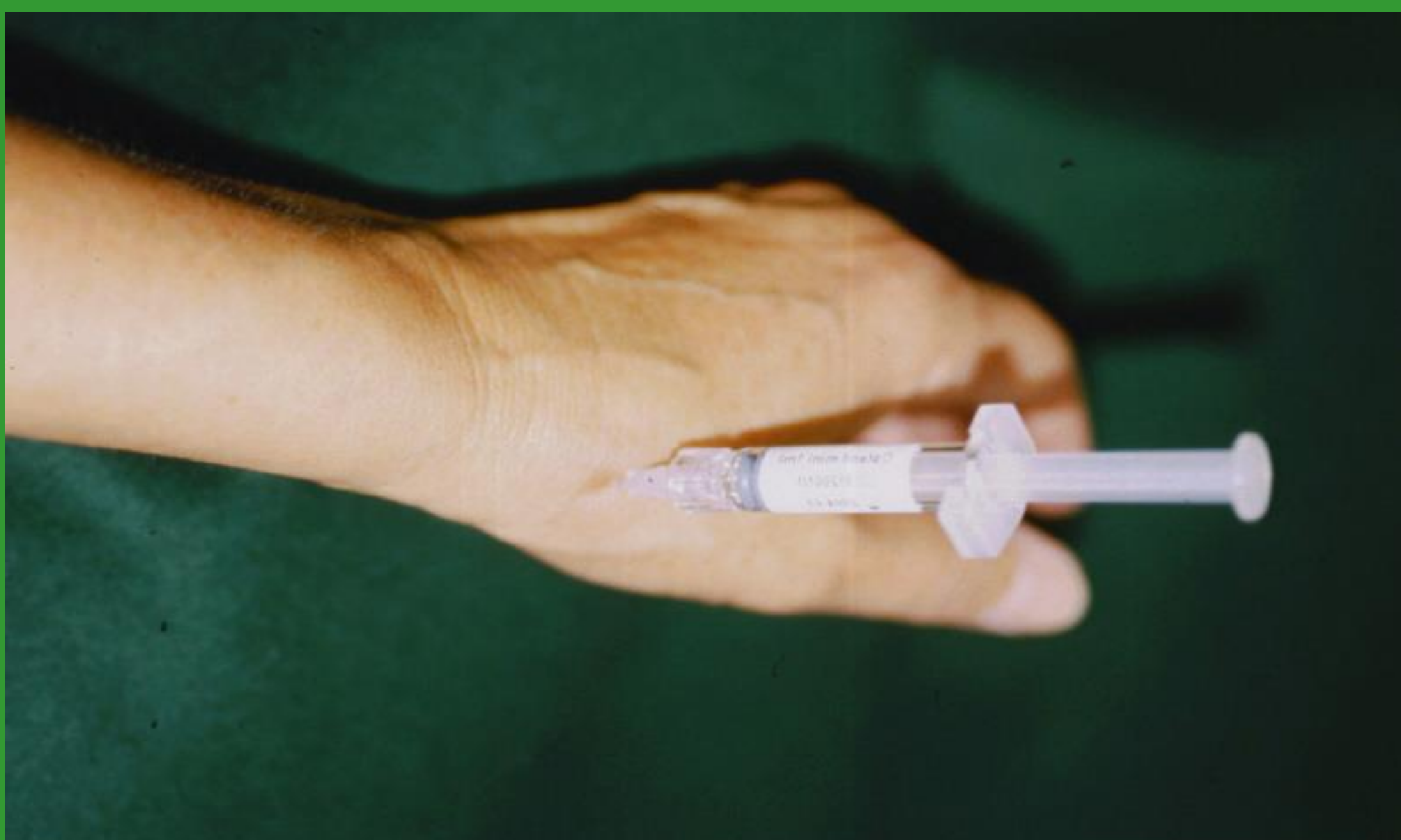Aim

To investigate the efficacy and safety of intra-articular sodium hyaluronate in patients with osteoarthritis of the carpometacarpal joint in an open, prospective clinical study.

Rationale

Osteoarthritis of the carpometacarpal joint is a very common problem in elderly patients. Pain and degeneration of joint structures may adversely affect joint function and the quality of life. Current conservative treatment includes physiotherapy, analgesics, NSAIDS, and intra-articular glucocorticoids, respectively.

Hyaluronic acid plays an important role in the synovial fluid and joint cartilage. In osteoarthritis, the quality and quantity of endogenous hyaluronic acid in the joint is reduced. Viscosupplementation with hyaluronic acid has been shown to have a favourable effect on pain and restricted joint mobility in patients with knee osteoarthritis by several investigators.



Injection into the carpometacarpal joint

Patients, Methods and Material

Patients:

- 20 patients (mean age 66.8 ± 6.5 years) suffering from severe pain due to, radiologically ascertained, osteoarthritis of the carpometacarpal joint

Test product:

- 10 mg/1ml fermentative sodium hyaluronate (Ostenil® mini pre-filled syringes, specifically developed for smaller joints)

Treatment protocol:

- two to three intra-articular injections in weekly intervals

Efficacy parameters:

- pain reduction (Huskisson 100 mm visual analogue scale for pain, VAS)
- grip strenght (pinch grip and lateral grip), using an intrinsimeter
- crepitation during passive movement of the joint
- joint mobility (radial and palmar abduction and adduction)
- global clinical impression of investigator and patients
- "Immediate" effects were assessed during treatment (visits 1 to 4) and "carry over" effects three months after treatment (visit 5)

Safety:

- assessed by documentation of clinically evident adverse events

References

- Talke M. Intraarticular hyaluronic acid in osteoarthritis of the carpometacarpal joint. Akt Rheumatol 27:101-106, 2002
- Talke M, Dobner P, Naserke K. A new option in osteoarthritis of the first carpometacarpal joint: intraarticular hyaluronic acid. Orthopädische Praxis 38, 7:495-501, 2002

Results

- No unexpected or adverse events were reported.
- Pain was markedly reduced from $64.0 (\pm 11.1)$ mm VAS on visit 1 to $39.3 (\pm 13.2)$ mm VAS on visit 5 (39% reduction). Reduction was more pronounced in patients with Kellgren II and III (Fig. 1).
- Grip strength increased 37% for the lateral grip (V1: 2.1 ± 0.7 grades, V5: 2.9 ± 1.0 grades) and 38% for the pinch grip (V1: 1.5 ± 0.5 grades, V5: 2.1 ± 0.9 grades). Differences reached statistical significance ($p < 0.001$, Friedman test) (Fig. 2).
- Joint mobility showed a marked improvement on radial (V1: 51.8 ± 13.3 grades, V5: 56.5 ± 10.8 grades) and palmar (V1: 47.8 ± 10.8 grades, V5: 51.8 ± 9.9 grades) abduction (data not shown).
- Crepitation persisted in only 3 out of 11 patients (data not shown).
- In 19 out of the 20 cases, investigator and patients were satisfied with the improvement in signs and symptoms (Fig. 3).

Figure 1: Reduction in pain

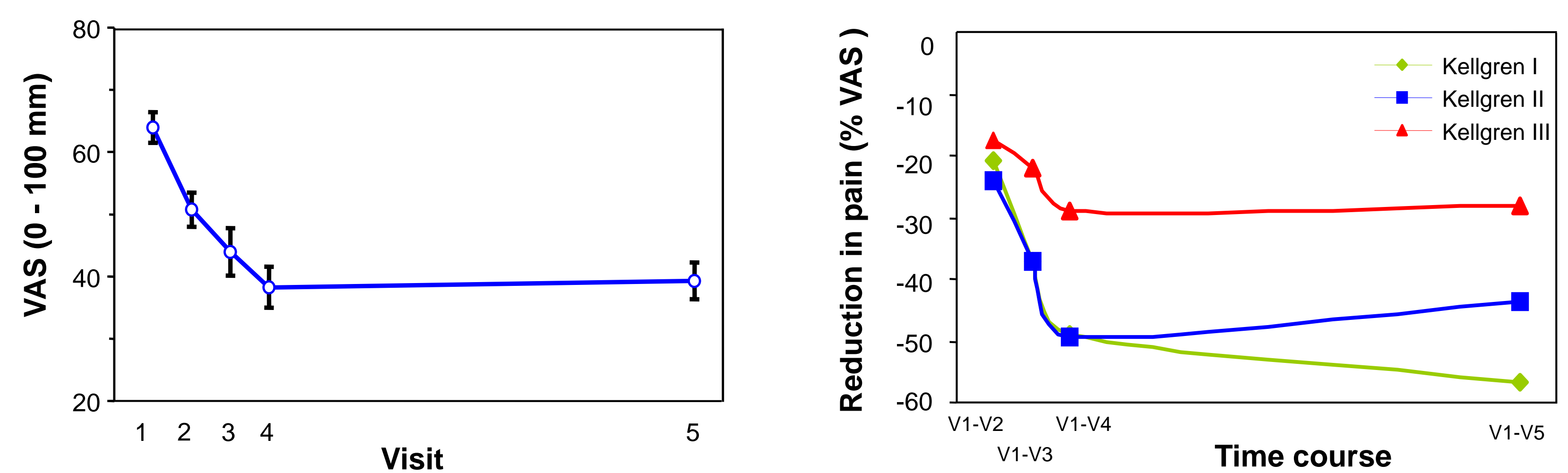


Figure 2: Increase in grip strength

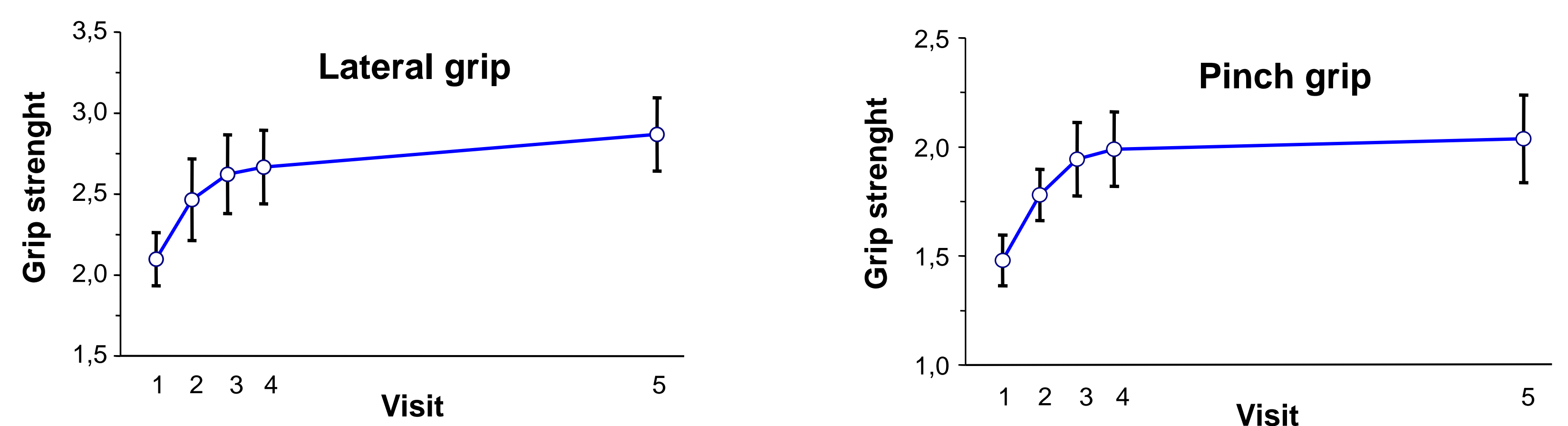
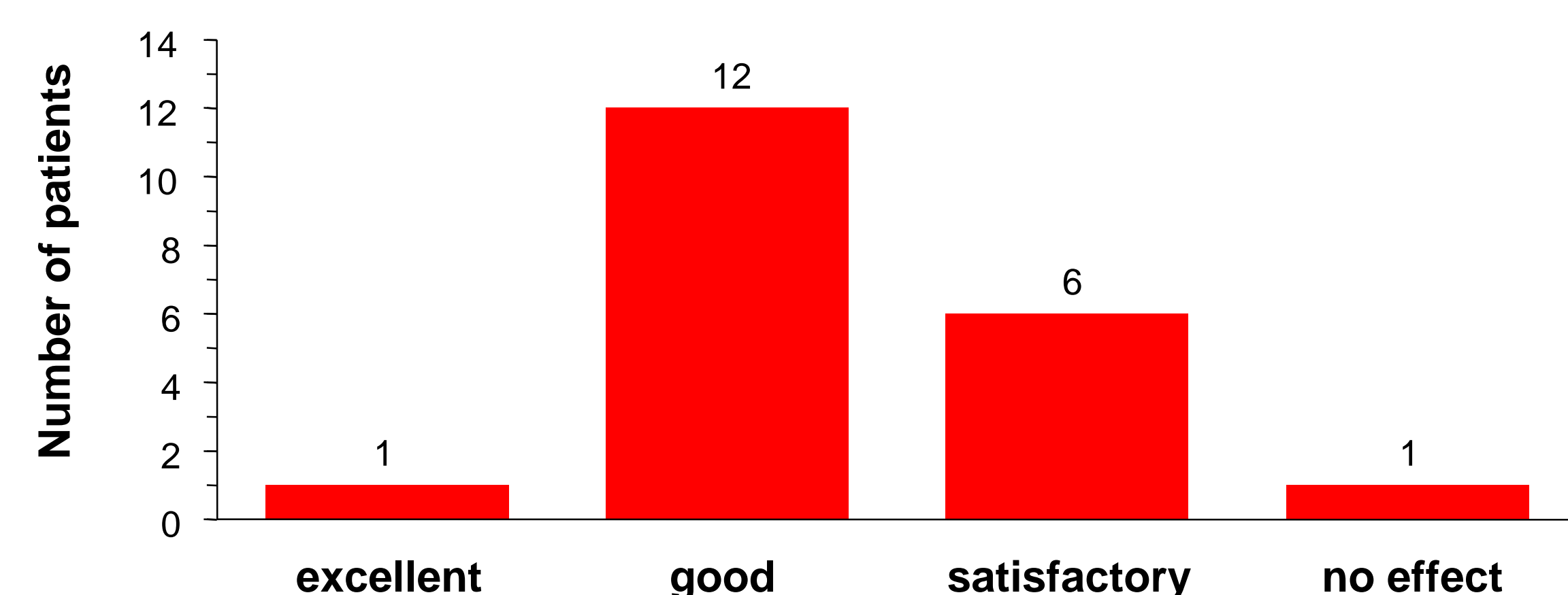


Figure 3: Satisfaction of patients with improvement in pain and function



Conclusion

Intra-articular hyaluronic acid is a promising new option in the treatment of osteoarthritis of the carpometacarpal joint, as the benefit -risk-evaluation favours the use of hyaluronic acid in this indication.